

# The Tricuspid Insufficiency—Pulsating Varicocele Connection:

A Syndrome and Its History

Herbert L. Fred, MD, MACP

**C**ardiologists rarely examine the scrotum, and men with scrotal problems rarely consult cardiologists. There are times, however, when each should.

## Puzzling Abnormality

When I was an intern in 1954, one of my patients was a 24-year-old man who had cardiac failure consequent to rheumatic heart disease. On physical examination, he had prominent systolic waves in his jugular venous pulse and murmurs of mitral and tricuspid insufficiency. The most striking finding, however, was a left-sided, non-tender scrotal mass—believed to be an enlarged testicle—that pulsated with each heartbeat, without associated murmur or thrill. He had not been aware of this abnormality and reported no genital complaints. None of the students, house officers, or attending physicians on the various ward teams had ever seen or heard of a similar finding. Despite our curiosity, the severity of the patient's heart disease prevented definitive investigation of the mass. (In those days, reliable noninvasive methods of studying the scrotum were not available.) Consequently, the precise nature of the mass and the reason for its pulsations remained conjectural for the next 24 years.

## Clarification

The mystery ended for me in 1978, when physicians from California described the case of a 39-year-old man with rheumatic heart disease who presented with a one-year history of pain and swelling in his scrotum.<sup>1</sup> On admission, he had congestive heart failure; results of subsequent cardiac catheterization indicated severe tricuspid insufficiency (TI). Examination of his scrotum uncovered a prominent right-sided varicocele (dilated or tortuous veins of the pampiniform plexus within the spermatic cord) and a moderate-sized, mildly tender, pulsatile left-sided mass. A left gonadal venogram showed the mass to be a large varicocele. The authors attributed its pulsations to the widened venous pulse pressure of TI coupled with the frequent absence or incompetence of valves in left-sided gonadal veins of men.

Because this case and mine were remarkably similar, I concluded that the scrotal mass in my patient must have been a pulsating varicocele (PV)—not a pulsating testicle as I had originally thought.

Together, these 2 cases suggested a link between TI and PV. The suggestion made physiologic sense, but it raised important questions. Are 2 cases enough to validate the link? Have other similar cases been reported? Do other peripheral veins pulsate in patients with TI? Why is PV so rare when heart failure with TI is so frequent and when 20% of men have varicoceles?<sup>2</sup>

## Building Evidence

For answers, I launched a 2-step review of the medical literature, focusing initially on PV, then on TI. Step 1 yielded 3 additional cases of PV in foreign medical publications.<sup>3,4</sup> One of them stands as the first case of PV ever reported.<sup>3</sup> It concerned a 22-year-old man in Argentina who, coincidentally, had come under observation the same year as did my patient (1954). He had severe cardiac failure of unstated cause, but the evidence strongly favored rheumatic heart disease. His physical examination showed cardiomegaly, a regular heart rate, prominent systolic pulsations in distended

**Key words:** *Diagnosis, differential; heart failure/complications; history of medicine, 19th century; history of medicine, 20th century; pulsatile flow/physiology; scrotum/blood supply; tricuspid valve insufficiency/complications; varicocele/complications/diagnosis/etiology/physiopathology; varicose veins/complications; veins/physiology; venous pressure*

*Dr. Fred is an Associate Editor of the Texas Heart Institute Journal.*

*Reprints will not be available from the author.*

**E-mail:** [hlf1929@yahoo.com](mailto:hlf1929@yahoo.com)

© 2017 by the Texas Heart® Institute, Houston

jugular veins, systolic thrills over the mitral and tricuspid areas, functional TI, a pulsatile liver, lower-leg edema, and bilateral varicoceles with veins that were “thick as thumbs.” On inspection and palpation, both varicoceles pulsated in synchrony with the systemic pulse. The patient had not reported a scrotal problem but did say that his scrotum became larger when he stood up. His physician attributed the varicoceles to venous hypertension (venous pressure increased from 19 cm H<sub>2</sub>O to 26 cm H<sub>2</sub>O when the patient raised his legs) and concluded that PV is another sign of TI.

The second and third cases were reported in a single publication from Romania in 1967.<sup>4</sup> Both patients presented with worsening signs and symptoms of congestive heart failure. Neither, however, was aware of his scrotal abnormality. One patient was 25 years old, and the other, 38 years old. Both had rheumatic heart disease with cardiomegaly, atrial fibrillation, and murmurs of mitral stenosis and TI. The younger patient had a pulsatile liver and a right-sided PV, whereas the older patient had bilateral PVs, more prominent on the right. In both patients, the superficial scrotal veins were dilated. A transducer placed over the jugular veins, liver, and scrotum recorded nearly identical venous pressure waveforms that differed only in progressively diminishing amplitude and upstroke as distance from the right ventricle increased. That diagnostic approach—a forerunner of venous Doppler imaging<sup>5,6</sup>—provided strong technical evidence of a link between TI and PV.

This report was especially noteworthy because it cited evidence from other investigators that TI can cause peripheral venous pulsations in almost any part of the body. That evidence effectively answered one of the questions that I had posed earlier.

### **Bolstering the Connection**

Step 2 uncovered a wealth of information on TI and pulsating peripheral veins, leaving no doubt that a link between the 2 entities does exist. For example, in patients with TI, venous pulsations have been observed largely in the forehead, neck, and forearms, but also in the eyeballs, retinas, buttocks, thighs, lower legs, and femoral area; the liver and spleen can pulsate as well.<sup>7,8</sup>

Pulsating peripheral veins were noted as early as 1815.<sup>9</sup> Their mechanism was debatable until 1836, when Benson<sup>10</sup> correctly contended that they were consequent to a regurgitant impulse from the right ventricle through the auriculoventricular orifice into and throughout the distended veins, no matter how competent the venous valves might be. In 1866, Friedreich<sup>11</sup> considered liver pulsations to be pathognomonic of TI. Then, in 1925, Kerr and Warren<sup>12</sup> emphasized that pulsating peripheral veins were an almost constant sign of TI, that their early appearance heralded the onset of cardiac failure, that their magnitude was proportional to the degree of cardiac failure, and that their detection depended on the

diligence with which they were sought. And, in 1936, Teufl<sup>13</sup> pointed out that if the venous pulsations disappeared when right-sided heart failure ended, the valve itself was normal and the TI was relative (functional). Conversely, if the venous pulsations persisted after signs of heart failure had disappeared, the valve was diseased and the TI was organic in nature.

My review led me to an important conclusion: except for rupture of an abdominal aneurysm into the vena cava,<sup>14,15</sup> and excluding rare and controversial instances among chronic intravenous-drug users,<sup>8,16</sup> *pulsating peripheral veins are pathognomonic of TI.*

Inexplicably, interest in pulsating peripheral veins either waned or never took hold. Whatever the reason, articles on this subject have appeared only occasionally since Teufl's report in 1936.<sup>7,8,17-20</sup> That might explain why many physicians today are like I was in 1978—generally clueless about pulsating peripheral veins.

One other point merits consideration: given the attention that physicians gave to pulsating peripheral veins during the 1800s and early 1900s, I was surprised to find no mention of a PV in the literature of those years.

### **Unexpected Add-On**

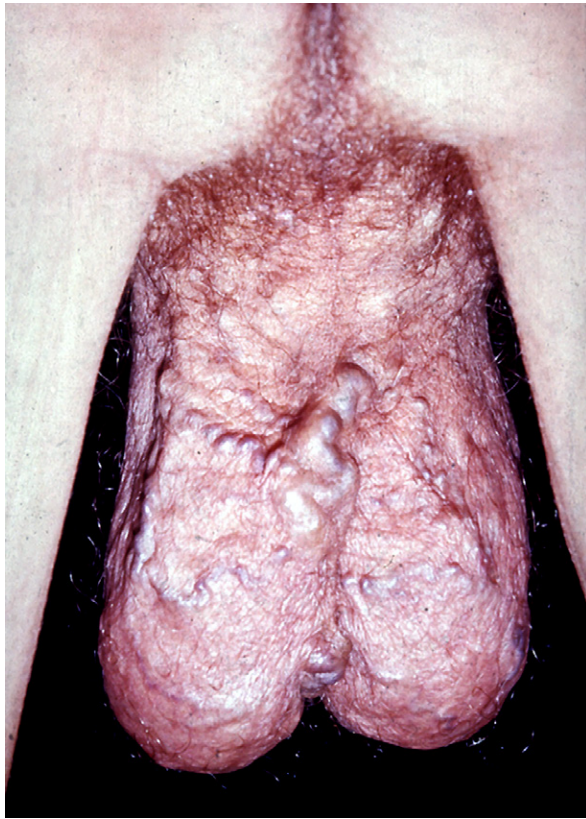
At this juncture, I had assembled reports on 5 patients with congestive heart failure, prominent TI, and PVs. Curiously, in none of these reports were systolic venous pulsations mentioned anywhere on the body other than in the neck and scrotum. Still unanswered was the question of why PVs are so rare when heart failure, TI, and varicoceles are so prevalent. In addition, I never expected to encounter another PV. But I was wrong again.

In 1986, a 19-year-old man with Ebstein anomaly and acute heart failure came under my care. This time, I took advantage of what I had learned from my literature review and examined him carefully. He had sinus rhythm, cardiomegaly, congested lungs, a harsh systolic murmur in the tricuspid area, prominent systolic pulsations in distended jugular veins, lower-leg edema, and conspicuous scrotal varices, especially on the left (Fig. 1). Although the varices did not pulsate, an asymptomatic left-sided scrotal mass did. Results of a radionuclide technetium scrotal scan confirmed my clinical diagnosis of PV.<sup>21</sup> None of his other peripheral veins pulsated. As his heart failure improved, the magnitude of pulsations in his varicocele diminished.

This case of PV is the sixth overall and, as far as I can determine, the first to result from congenital disease of the tricuspid valve. Now, as of 2017, I am unaware of other reported cases.

## **Discussion**

Each case by itself would be considered a medical oddity. Together, however, these 6 cases constitute a distinct syndrome characterized by the unique combination of



**Fig. 1** Photograph shows prominent scrotal varices, especially on the left.

tricuspid insufficiency from any origin (the cause) with a pulsating varicocele (the effect). Because either abnormality can be the presenting manifestation, careful physical examination of the heart and of the scrotum is all that it takes to make the diagnosis. I suspect that additional examples of this relationship have been observed but not reported, or perhaps reported but not found during my review of the relevant medical literature. Either way, I titled this article to underscore the syndrome's mechanism, specify its 2 essential elements, and facilitate its recognition.

Five of these patients presented with heart failure. One patient presented with pain and swelling in his scrotum, but he, too, had concomitant heart failure and evidence of severe TI upon cardiac catheterization. The origin of TI was rheumatic heart disease in 5 and Ebstein anomaly in 1.

The PV was left-sided in 3 patients, right-sided in 1, and bilateral in 2. One patient had noticed that his scrotum became larger when he stood up, but there was no associated discomfort. Four patients did not know that they had a scrotal abnormality.

Among pulsating scrotal masses—all extremely rare—varicocele is the only one directly linked to TI. Therefore, if the affected patient does not have TI, he

does not have PV. He has, instead, one of the 3 other types of pulsating scrotal masses:

- 1) arteriovenous malformation (which has a murmur and thrill)<sup>22</sup>;
- 2) “arteriocele” (enlarged internal spermatic artery providing collateral blood supply to the right lower limb in men with distal aortic—Leriche syndrome<sup>23</sup>—or iliac artery<sup>24</sup> occlusion); or
- 3) dilated scrotal arteries perfused at high flow after aortobifemoral bypass surgery and accompanied by a high-pitched scrotal systolic murmur.<sup>25</sup>

In each of these conditions, the medical history and physical findings should point immediately to the fundamental cause and enable appropriate corrective therapy. If diagnostic uncertainty remains, results of radionuclide scanning,<sup>21</sup> ultrasonography,<sup>26,27</sup> or angiography<sup>22-25</sup> of the scrotum will settle the issue.

### Take-Home Message

- Any man with TI should have his scrotum examined for PV.
- Any man with PV should have his heart examined for TI.
- All patients with TI should be examined carefully for pulsating peripheral veins, and all patients with pulsating peripheral veins should be examined for TI.
- With the 2 exceptions noted, pulsating peripheral veins (including varicoceles) are pathognomonic of TI.

### Addendum

On 13 September 2017, I formally named the described constellation of physical findings “The Fred Syndrome.”

*James T. Willerson, MD,*  
*Editor-in-Chief,*  
 Texas Heart Institute Journal

### Acknowledgments

I thank my translators, Dr. Gabriel Aisenberg (Spanish) and Drs. Catalin Loghin and Dana Giza (Romanian). I thank Sonya E. Fogg, MLS (Manager, Library and Learning Resource Center, Texas Heart Institute), for confirming and providing links to the historical references.<sup>9-11,13</sup>

### References

1. Smith DC, Reardon MS, Hadley HL. Large varicocele presenting as pulsatile scrotal mass. *Urology* 1978;11(5):529-30.
2. Masson P, Brannigan RE. The varicocele. *Urol Clin North Am* 2014;41(1):129-44.
3. Contardi JC. Pulsatile bilateral varicocele [in Spanish]. *Sem Med* 1955;106(25):941, 948.

4. Paunescu C, Ioan A, Popa F. Pulsatile varicocele, an unusual manifestation in tricuspid insufficiency [in Romanian]. *Med Interna (Bucur)* 1967;19(11):1389-96.
5. Abu-Yousef MM, Kakish ME, Mufid M. Pulsatile venous Doppler flow in lower limbs: highly indicative of elevated right atrium pressure. *AJR Am J Roentgenol* 1996;167(4):977-80.
6. Kakish ME, Abu-Yousef MM, Brown PB, Warnock NG, Barloon TJ, Pelsang RE. Pulsatile lower limb venous Doppler flow: prevalence and value in cardiac disease diagnosis. *J Ultrasound Med* 1996;15(11):747-53.
7. Brickner PW, Scudder WT, Weinrib M. Pulsating varicose veins in functional tricuspid insufficiency. Case report and venous pressure tracing. *Circulation* 1962;25:126-9.
8. Ali N. Pulsations of arm veins in the absence of tricuspid insufficiency. *Chest* 1973;63(1):41-5.
9. Steinbuch. Ein Beitrag zur Gründung einer wissenschaftlichen Kenntnifs des Pulschlag[es] [in German]. *J der practischen Heilkunde* 1815;41B(3):3-64. Available from: <https://babel.hathitrust.org/cgi/pt?id=mdp.39015011938043;view=2up;seq=267>.
10. Benson C. Case of pulsation in the veins of the upper extremities. *Dublin J Med Chem Sci* 1836;8(23):324-31. Available from: <https://babel.hathitrust.org/cgi/pt?id=hvd.32044103058699;view=1up;seq=356>.
11. Friedreich N. Ueber den Venenpuls [in German]. *Dtsch Arch Klin Med* 1865;1(3-4):241-91. Available from: <https://babel.hathitrust.org/cgi/pt?id=hvd.32044103057600;view=2up;seq=254>. Figure 1 available from: <https://babel.hathitrust.org/cgi/pt?id=hvd.32044103057600;view=1up;seq=645>. Figure 2 available from: <https://babel.hathitrust.org/cgi/pt?id=hvd.32044103057600;view=1up;seq=647>.
12. Kerr WJ, Warren SL. Peripheral pulsations in the veins in congestive failure of the heart, associated with pulsation of the liver and tricuspid regurgitation. *Arch Intern Med* 1925;36(5):593-613.
13. Teufl R. Pulsation normaler und variköser Extremitätenvenen und ihre diagnostische Bedeutung [in German]. *Wien Med Wchnschr* 1936;86:288, 352, 407, 436.
14. Colley AL, Annon WT Jr. Aortic-vena caval fistula from ruptured aortic aneurysm. *JAMA* 1965;194(10):1137-8.
15. Gilling-Smith GL, Mansfield AO. Spontaneous abdominal arteriovenous fistulae: report of eight cases and review of the literature. *Br J Surg* 1991;78(4):421-5.
16. Cheng TO. Letter: pulsations of arm veins in absence of tricuspid insufficiency. *Chest* 1974;65(2):235-6.
17. Hallock P, Clarke WO. Significance of generalized systolic pulsation of veins, with report of a case in which there was marked pulsation of varicose veins. *Am Heart J* 1941;22(3):410-6.
18. Blackett RL, Heard GE. Pulsatile varicose veins. *Br J Surg* 1988;75(9):865.
19. Chow WH, Cheung KL. Pulsatile varicose veins--a sign of tricuspid regurgitation. *Br J Clin Pract* 1990;44(12):669.
20. Dalla Vestra M, Grolla E, Bonanni L, Dorrucchi V, Presotto F, Rigo F. From the veins to the heart: a rare cause of varicose veins. *Case Rep Vasc Med* 2015;2015:849408.
21. Golimbu M, Florio FE, Al-Askari S, Morales PA, Passalacqua A. Value of scrotal scanning. Report of 62 cases. *Urology* 1985;25(1):89-92.
22. Kapadia S, Yadav A, Parakh R. Snapshots in surgery. Pulsatile scrotum. *Br J Surg* 2006;93(10):1223.
23. Lendvay TS, Tandon S, Lumsden AB, Petros JA, Issa MM. Pulsatile mass in the scrotum in a man with the Leriche syndrome. *J Urol* 2002;167(1):257-8.
24. Conroy RM, Molen RL. Scrotal "arteriocele" from iliac artery occlusion. *AJR Am J Roentgenol* 1976;127(4):670-2.
25. El-Hakim A, Ponsot Y, Benko A. Revascularized internal iliac artery aneurysm presenting as a painful pulsatile scrotal mass after aortobifemoral bypass surgery. *Urology* 2003;62(5):941.
26. Ozkardes H, Konecoglu AG. Scrotal thrill: an unusual finding in high-grade varicocele. *Int Urol Nephrol* 1993;25(6):583-5.
27. Dohle GR, Schroder FH. Ultrasonographic assessment of the scrotum. *Lancet* 2000;356(9242):1625-6.